

Summarised from *Journal of Clinical Periodontology*, Volume 48, issue 11 (November 2021), 1480-1490

Editors: Phoebus Madianos & Andreas Stavropoulos, EFP scientific affairs committee

**Rapporteurs:**

Naz Kurt, Ahmet Duranay, and Canberk Kemik with Hare Gürsoy and Prof Bahar Eren Kuru

**Affiliation:**

EFP-affiliated postgraduate programme in periodontology at Yeditepe University, Istanbul, Turkey

*study*

# Short implants: two adjacent or a single implant with a cantilever?

**Authors:**

Daniel S. Thoma, Karin Wolleb, Roman Schellenberg, Franz-Josef Strauss, Christoph H.F. Hämmerle, and Ronald E. Jung

## Background

The length of the implants is an important factor during implant treatment planning. In the posterior areas, vertical bone height is usually limited either by the maxillary sinus or by the inferior alveolar nerve. This often leads to a preference for shorter implants. Reviews have suggested that survival rates of rough-surfaced short implants are similar to those of longer implants.

In clinical situations where there are two-unit gaps in the posterior maxilla and mandible, two options are indicated for restoring function and aesthetics: two adjacent implants or a single implant with a cantilever.

One-to-one, single-tooth short implants are the most well-documented treatment modality and present high survival rates after five years in terms of implant and restorative aspects. The placement of a single implant with a cantilever may have advantages such as less patient morbidity, a shorter treatment time, and lower cost. This approach offers an alternative in unfavourable anatomical conditions.

However, it has been hypothesised that cantilevers may increase occlusal and functional forces on the implant, jeopardising the success together with unfavourable peri-implant parameters. There is a lack of information in the literature on the clinical outcomes comparing two single implants versus a single implant with a cantilever.

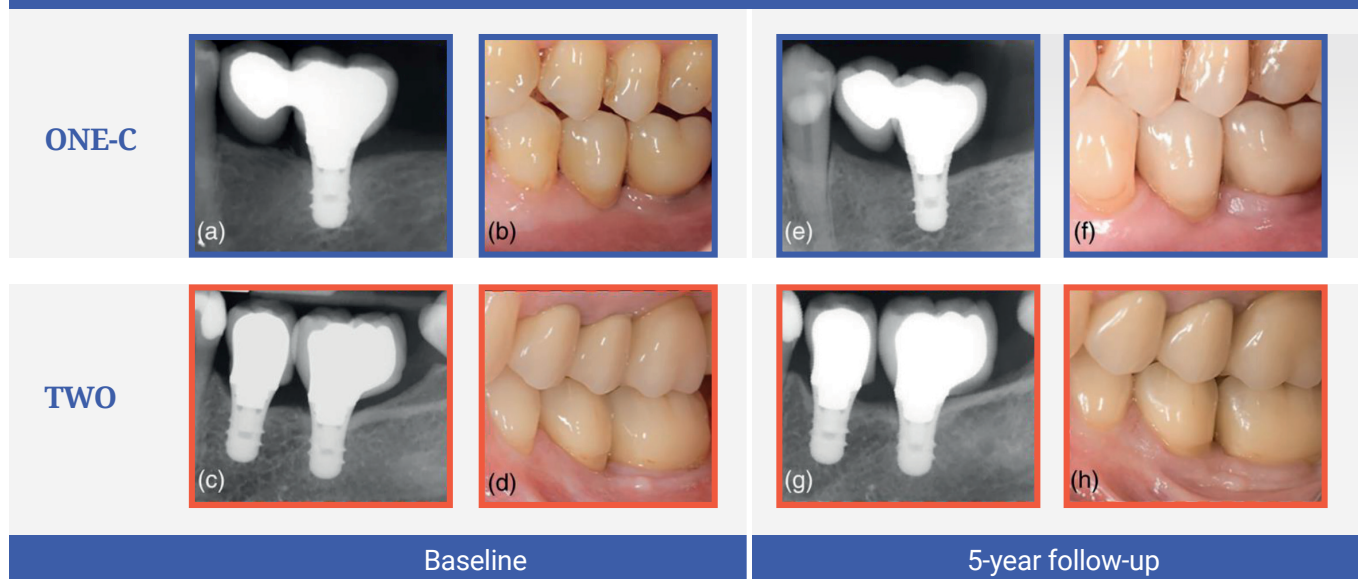
## Aim

The aim of this study was the clinical, radiographic, and technical evaluation of the use of one short implant with a cantilever versus two adjacent short implants with single-tooth reconstructions after five years of functioning.

## Materials & methods

- This prospective, parallel-design randomised clinical trial included patients requiring fixed implant-supported dental prosthesis for two-unit gaps.
- Smokers (more than 15 cigarettes per day), people with active periodontal disease, and pregnant or breastfeeding women were excluded.
- Participants were randomly assigned into two groups to receive either one short implant (group ONE-C) or two short implants (group TWO). All implants were 6mm in length and had a diameter of 4.1mm. A total of 54 "Straumann Standard Plus" implants were placed in 36 patients (18 in group ONE-C and 18 in group TWO). Surgical procedures were performed according to standard protocols and the manufacturer's recommendations. In cases of bone deficiency, guided bone regeneration was performed. Fixed prostheses were inserted three to six months after implant surgery.
- Baseline examinations were performed one to three weeks after final prosthesis placement. All patients were placed in a supportive periodontal care programme and re-examinations were performed at six months and at one, three, and five years after prosthesis placement.
- The primary outcome was radiographic marginal bone loss (MBL) calculated as the mean of mesial and distal MBL. Changes in MBL from baseline to six months and one, three, and five years were estimated. Implant survival (implant being in place and stable) and reconstruction survival (reconstruction being in situ) rates were estimated after five years.
- Biological complications (peri-implant mucositis and peri-implantitis) and technical complications (implant/abutment fracture, chipping, and loosening of the abutment screw) were also evaluated.
- Clinical parameters (probing depth, bleeding on probing, and plaque scores) were evaluated at the follow-up examinations.

**Figure:** Representative cases of each treatment modality



Periapical radiographs (a,c) and clinical situation (b,d) at baseline (crown delivery). Periapical radiographs (e,g) and clinical situation (f,h) at five-year follow-up.

## Results

- The study was completed with 26 patients (15 in group ONE-C and 11 in group TWO).
- Implant survival rates were 84.2% in ONE-C versus 80.4% in TWO after five years. Two patients had early failure before loading (one in each group). Four late failures occurred, two in each group. In ONE-C, one implant failed after prosthesis delivery and the other six months after loading; in TWO, two implants failed after three years.
- Twenty-five technical complications were seen in 16 implants (18 in ONE-C and seven in TWO). Rates of these technical complications were 64.2% in ONE-C versus 54.4% in TWO. No statistically significant differences were detected between the groups.
- From baseline to five years of loading, the median MBL changes were 0.13mm in ONE-C and 0.05mm in TWO, without a statistically significant difference. Likewise, no statistically significant differences were observed between the groups in terms of MBL changes at any time point.
- Prevalence of peri-implant mucositis was 56.2% in ONE-C versus 63.6% in TWO, without statistically significant difference. Peri-implantitis was not observed.
- There was no statistically significant difference between the two groups in probing-depth, plaque, and bleeding-on-probing scores.

## Limitations

- After five years, only 26 of 36 participants were available for review, which limited the power of the study.
- Two different jaws, maxilla and mandible, with different posterior bone quality were included.
- Clinical variables such as implant location, mesial/distal cantilevers, unstandardised surgical procedures (such as application of guided bone regeneration), and type of placement (submerged or transmucosal) may have affected the results.
- One of the figures used - on representative cases of each treatment modality - is controversial because the representative case for group TWO has faulty superstructure in terms of an inappropriate distally extended single-crown unit without a distal contact.
- No information was given as to whether the clinical measurements were standardised by a single investigator.

## Conclusions & impact

- Both treatment options revealed similarly modest survival rates after five years of functioning. However, short implants with a cantilever were more prone to earlier failure, suggesting that the implant was overloaded.
- Similar clinical, radiographical, and technical outcome parameters were seen in both treatment modalities during the five-year follow-up period.
- Similar rates of biological complications were seen between both treatment modalities over the five years.
- In daily practice, when reconstructing two-unit gaps in the posterior area of the jaws, the clinical indication of both treatment options should be carefully evaluated.



JCP Digest 95 is a summary of 'Two short implants versus one short implant with a cantilever: 5-Year results of a randomized clinical trial'  
*J Clin Periodontol.* 48 (11): 1480-1490. DOI: 10.1111/jcpe.13541



<https://www.onlinelibrary.wiley.com/doi/10.1111/jcpe.13541>



Access through EFP members' page log-in: <http://efp.org/members/jcp.php>