

**Rapporteurs:**

Chin Hoi Man Bonnie, Kwok Chee Yin, Lam Pok Man,  
and Tsang Nichol Chun Wai, with George Pelekos

**Affiliation:**

EFP-affiliated programme in periodontology at the University  
of Hong Kong

*study*

# Implant placement with soft-tissue grafting: when and how?

**Authors:**

Kwang-Seok Lee, Seung-Yun Shin, Christoph H. F. Hämmerle, Ui-Won Jung, Hyun-Chang Lim, and Daniel S. Thoma

## Background

Soft-tissue grafting procedures are often performed to improve aesthetic outcomes and to compensate for existing volume deficiencies. Clinical data have demonstrated that soft-tissue surgery contributes to more than 40% of the final horizontal or buccal volume. The "gold-standard" procedure for soft-tissue volume augmentation is the use of a subepithelial connective-tissue graft (CTG). However, harvesting procedures cause increased patient morbidity because of the presence of a donor site.

Soft-tissue substitutes were developed to overcome these issues. In pre-clinical canine studies, soft-tissue substitutes and CTG demonstrated a similar effect on soft-tissue volume increase at implant sites. A recent clinical study (Thoma et al., 2016) indicated the non-inferiority of soft-tissue substitutes for implant sites compared with CTG. However, previous data regarding soft-tissue substitutes are limited to specific implant treatment protocols and, more specifically, to delayed placement.

Considering that various treatment protocols exist – such as immediate implant placement (IP), early implant placement (EP), and implant placement following alveolar ridge preservation (ARP) – the effectiveness of soft-tissue substitutes for soft-tissue volume augmentation using different implant placement protocols needs to be further evaluated and compared with CTG.

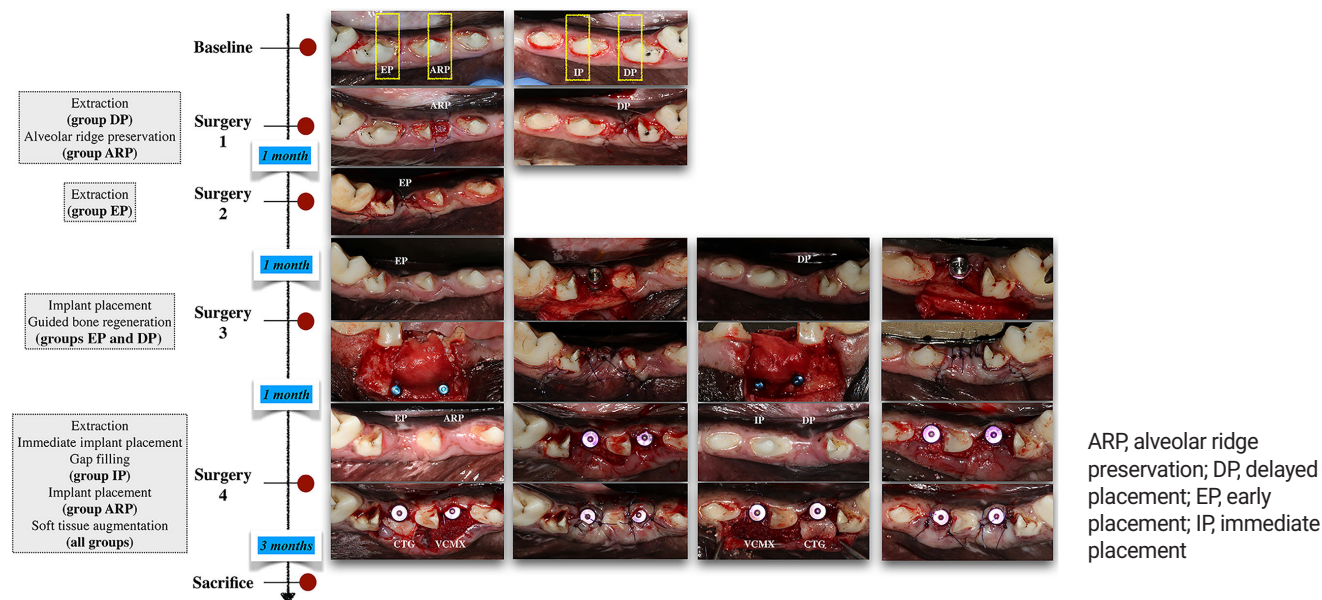
## Aim

The aim of this study is to determine the effect of the timing of implant placement and the type of soft-tissue graft in terms of changes to the ridge profile.

## Materials & methods

- The third mandibular and fourth premolars were hemisected and the mesial roots extracted. The implants were 4 x 10 or 12mm, Luna, Shinhung, Seoul, Korea, and the healing abutments were 4 x 4mm.
- ARP was performed with deproteinised bovine bone material (DPBM) with 10% collagen (Bio-Oss collagen, Geistlich, Wolhusen, Switzerland) and a collagen matrix (Mucograft seal, Geistlich), and implant installation was performed after three months of healing.
- IP was combined with deproteinised bovine bone mineral (Bio-Oss, Geistlich) filling the gap between the implant and the buccal bone plate.
- Implant installation at the EP and DP groups was performed one and two months after extraction respectively, and included guided bone regeneration (GBR) using deproteinised bovine bone mineral (Bio-Oss, Geistlich) and a native bilayer collagen membrane (BioGide, Geistlich) at the buccal aspect of the implant. EP and DP implants were exposed after one month of healing.
- In all groups, a partial-thickness flap was raised at the buccal side of the implants for either a CTG or VCMX (Fibrogide, Geistlich).
- All the animals were sacrificed months after soft-tissue surgery. Microcomputed tomography scanning and intraoral scanning were performed at different time points. Linear measurements were performed to observe the ridge-contour changes between different timepoints. The overall change of ridge width throughout the study, the change resulting from bone augmentation, and the change caused by soft-tissue augmentation were measured.
- Profilometric measurement was obtained at a region 2mm apical to the gingival margin and extended 2mm apically with a 4mm width. Changes across timepoints were observed.

**Figure:** Flow-chart and clinical photographs of the surgeries.



## Results


- No adverse event was observed.
- Micro-CT scans revealed bone remodelling around implants, and bone dehiscences were observed on the buccal surface. The IP group showed the most favourable result.
- Linear measurement:
  - Overall change
    - 2mm level – all except ARP/CTG (0.07mm) demonstrated horizontal shrinkage, ranging from -0.09mm in DP/VCMX to -1.87mm in EP/CTG.
    - 3mm level – similar ridge width was found in DP/CTG (0mm) and ARP/CTG (0.03mm), otherwise there was shrinkage, ranging from -0.13mm in EP/VCMX to -1.59mm in EP/CTG.
  - Hard tissue
    - 2mm level – gain in EP (0.87mm) and DP (0.93mm).
    - 3mm level – gain in EP (0.95mm) and DP (0.92mm).
  - Soft tissue
    - 2mm level – all except EP/VCMX (-0.20mm) demonstrated gain, ranging from 0.13mm in EP/CTG to 1.25mm in DP/CTG.
    - 3mm level – gain in all groups, ranging from 0.16mm in EP/VCMX to 0.97mm in EP/CTG.
- Profilometric measurement:
  - Overall change
    - Gains found in ARP/CTG (0.17mm) and DP/CTG (0.05mm), but losses were observed elsewhere, ranging from -0.02mm in ARP/VCMX to -1.19mm in EP/CTG.
  - Hard tissue
    - Larger median increase in DP (0.82mm) compared to EP (0.52mm).
  - Soft tissue
    - Gain in all groups, ranging from 0.14mm in DP/VCMX to 0.79mm in DP/CTG.
- No statistically significant differences within each group (overall, hard tissue, and soft tissue).


## Limitations

- The study may not be able to reflect the whole picture regarding soft-tissue remodelling after the procedures because animals were used and large clinical trials are necessary.
- There were no detailed discussions on the materials and methods used for the volumetric analysis in this study.

## Conclusions & impact

- Within the limitations of this study, ARP and DP with CTG led to the smallest tissue change between pre-extraction and the study's final time point, compared to other treatment modalities (without statistically significant difference).
- CTG and VCMX enhanced the overall tissue contour at the implant sites, when applied to EP or DP and ARP.
- Even though soft-tissue augmentation and gap filling were performed, IP sites had reduced tissue contours.
- Dimensional ridge changes varied between treatment protocols. ARP with CTG led to the smallest difference in ridge profile. Both CTG and VCMX were able to enhance the ridge contour.
- Based on the results of this pilot pre-clinical study, large clinical trials are required to determine the most favourable timing for implant placement and the preferred soft-tissue grafting modality for achieving optimal tissue profile.

 JCP Digest 100, published in May 2022, is a summary of 'Dimensional ridge changes in conjunction with four implant timing protocols and two types of soft tissue grafts: A pilot pre-clinical study.' *J Clin Periodontol.* 49(4):401-411. DOI: 10.1111/jcpe.13594

 <https://www.onlinelibrary.wiley.com/doi/10.1111/jcpe.13594>

 Access through EFP members' page log-in: <http://efp.org/members/jcp.php>